

Research Article



A Comparative Histopathological Study of Repaired Tendons Wrapped with Two Biological Matrices in Bucks

NADIA HAMD AL-FALAH^{*}, SERWA IBRAHIM SALIH

Department of Surgery and Obstetrics, College of Veterinary Medicine, Baghdad University, Baghdad, Iraq.

Abstract | This study was planned to evaluate the efficacy of two biological matrices represented by autologous platelet rich fibrin matrix (PRFM), as well as a cross linked decellularized caprine pericardial extracellular matrix (PECM) on enhancing healing of the experimentally severed superficial digital flexor tendon in a goat model. It was carried out on 48 adult bucks, which were divided randomly into three equal groups. Under sedation and regional anesthesia, SDFT was severed at the mid metacarpal region of the right forelimb. In the first control group, tenorrhaphy was performed and left without additives. While in the second group the tenorrhaphy site was wrapped with autologous platelet rich fibrin strips which were prepared at the time of operation, as well as in the third group the tenorrhaphy site was wrapped with a cross linked decellularized PECM strip which was previously prepared from the whole fresh caprine pericardium. The histopathological evaluation in this study revealed that the neovascularization, cellularity and collagen fiber alignment scores were significantly increased in both treated groups as compared to the control group. In conclusion, both biological matrices led to improvement in tendon healing and repair, without any complications, but the PECM gave superior results in tendon repair when compared to other groups.

Keywords | Flexor tendon healing, Pericardium extracellular matrix, Platelet rich fibre in matrix

Editor | Kuldeep Dhama, Indian Veterinary Research Institute, Uttar Pradesh, India.

Received | July 24, 2015; **Revised** | November 26, 2015; **Accepted** | December 01, 2015; **Published** | March 09, 2016

***Correspondence** | Nadia Hameed Rija Al-Falahi, Baghdad University, Baghdad, Iraq; **E-mail:** nadiaalfalahi@yahoo.com

Citation | AL-Falahi NH, Salih SI (2016). A comparative histopathological study of repaired tendons wrapped with two biological matrices in bucks. *Adv. Anim. Vet. Sci.* 4(3): 145-152.

DOI | <http://dx.doi.org/10.14737/journal.aavs/2016/4.3.145.152>

ISSN (Online) | 2307-8316; **ISSN (Print)** | 2309-3331

Copyright © 2016 AL-Falahi and Salih. This is an open access article distributed under the Creative Commons Attribution License, which permits unrestricted use, distribution, and reproduction in any medium, provided the original work is properly cited.

INTRODUCTION

Tendon injuries are considered as a significant clinical problem for orthopedic surgeons and investigators, recently many studies revealed the use of tissue engineering technologies and detected its beneficial effects in full-thickness injuries of tendon and ligament; therefore, various types of biomaterials have been used as a development technologies (Oryan et al., 2012). Tendons are slowly healed after injury with a poor spontaneous regeneration ability (Gigante et al., 2009; Song et al., 2010). Oryan et al. (2010) classified tendon injuries into acute and chronic, and they demonstrated that it also could be categorized by etiology; the most significant tendon injuries involved sharp tendon ruptures, tendinopathic forms of tendon ruptures and congenital or acquired defects which are characterized by impaired healing response. Sharma and Maffulli (2008) referred that tenorrhaphy is the most advantageous treatment for ruptured tendon, which provide good anastomo-

sis with minimal gap formation; but, if a large part of the tendon has been lost the elongation and transplantation techniques could be useful treatment for the defect area. Tissue engineering techniques have been developed as advancing strategies that aim to induce repair and replacement or regeneration of tissues and organs, a collagenous material considered as an excellent biomaterial which give promising effects on tissue regeneration and physical function of the injured tendons and ligaments (Juncosa-Melvin et al., 2005; Nicholson et al., 2007; Provencher et al., 2007; Kim et al., 2008; Lee, 2008; Sarrafian et al., 2010; Hao et al., 2010; Nillesen et al., 2011). Recent researches attempted to develop alternative non-toxic, easily prepared, and economically cheap therapeutics that lead to the local release of growth factors which accelerate hard and soft tissue healing. Platelet-rich fibrin (PRF) is an autologous platelet concentrates in a natural fibrin-based biomaterial prepared from autologous blood without anticoagulant to allow obtaining fibrin membranes concentrated with

platelets and growth factors that play a potential role in tissue engineering (Preeja and Arun, 2013). Thus the present study was designed to evaluate the histopathological changes of the repaired superficial digital flexor tendon experimentally underwent tenorrhaphy wrapped with two different biological matrices in bucks.

MATERIALS AND METHODS

Forty eight apparently healthy adult bucks, aged (1-2 years) weighed (20- 25 kg), were used in this study, these animals were examined clinically and ultrasonographically for any abnormalities of the SDFTs pre surgery. During the trial interval all animals were kept under same circumstances and dewormed with Ivermectin (Chongqing, china) administrated subcutaneously at a dose of (0.2 mg/Kg B.W.). Caprine pericardium was obtained from the local abattoir, immediately after slaughtering. The pericardium was submerged in saline solution in order to be transported to the laboratory; the tissue was gently rinsed with saline to get rid of the adhered blood. Mechanical cleansing was performed manually to eliminate all unwanted fat and connective tissues from the pericardium using dry gauze. The tissue was cut into 1X3cm size pieces (Figure 1), and were decellularized with 0.1% peracetic acid and 4% ethanol combination for two hours and cleaned with phosphate buffered saline (PBS) and deionized water for 15 min. (Brennan et al., 2006; Freytes et al., 2008), then cross-linked using 0.5% Glutaraldehyde (GA) in PBS for 72hr. The cross-linking was done at room temperature, washed in phosphate buffered saline (PBS). The prepared a cellular cross linked tissue matrices were stored at 4°C in PBS containing 1% gentamycin (Singh et al., 2013). Specimens from native and decellularized pericardium matrices were obtained and fixed in 10% buffered formalin, examined histologically by staining the sections using hematoxylin-eosin and Van-Gieson's stains to check the cellularity and the collagen component of both pericardium Specimens.

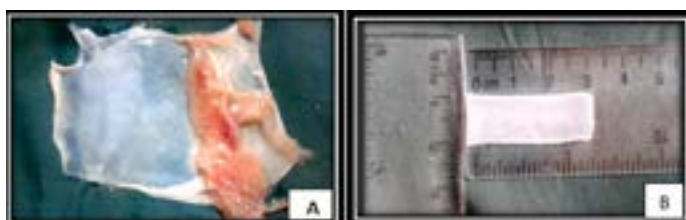


Figure 1: Shows steps of PECM preparation (A) manually cleansing of pericardium; (B) Trimmed pericardium (1x3 cm)

Platelet rich fibrin matrix was Prepared according to Dohan et al. (2006) method, 10-mL of blood samples were taken without anticoagulant in tubes, then immediately centrifuged at 3000 rpm for 10 minutes. Three separated layers resulted after centrifugation: the lower layer represented the red corpuscles, PRF matrix as a fibrin clot

presented in the middle, and the superficial layer represented a cellular platelet poor plasma (PPP). the matrix was withdrawn with forceps from the tube and cutting off the red blood corpuscles, then squeezing of PRFM from the fluid to obtain a fibrin membrane, then trimmed in a piece size of approximately (1X3cm) (Figure 2). Specimens from PRFM were taken and fixed in 10% buffered formalin, examined histologically by staining the sections using hematoxylin- eosin stain to observe the platelets and fibrin network.

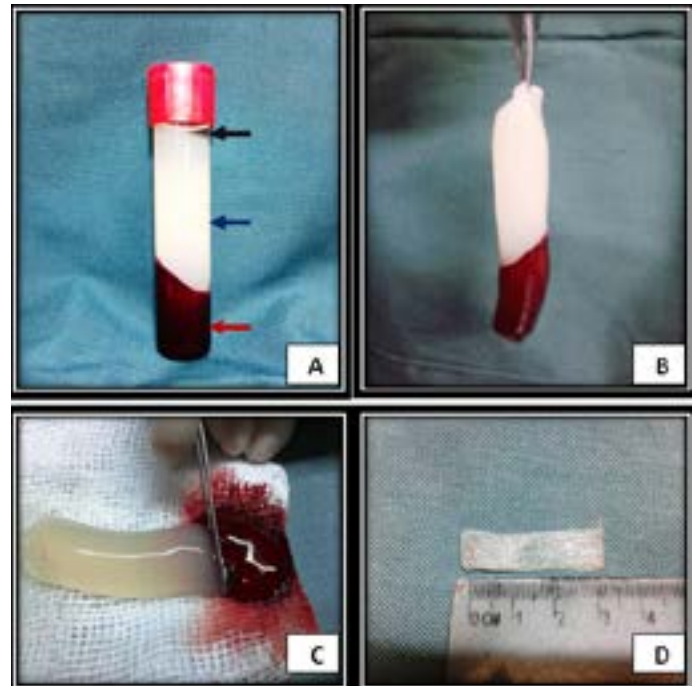


Figure 2: Steps of PRFM preparation (A) The blood sample following centrifugation, at the base of the tube the red corpuscles (red arrow), PRF matrix in the middle (blue arrow), the heigher layer represents acellular plasma (PPP) (black arrow); (B) Withdrawing the matrix from the tube with forceps.; (C) Cutting off the red blood corpuscles from PRFM; (D) PRFM membrane (1x3 cm).

SURGICAL PROCEDURE

Food was withheld for 24 hrs and water restricted 12 hrs prior to surgery. The animals were controlled in lateral recumbency after light sedation by using Xylazine ((Bayer-Germany) in a dose of 0.2 mg/Kg B.W. I/M (Fish et al., 2008) and The metacarpal region of the right forelimbs (between the carpal and fetlock joint) was prepared for aseptic surgical operations and tourniquet was applied above the carpal joint to control bleeding during operation, Ring block was performed in the fore limb using 2% lidocaine hydrochloride (Jayson Pharmaceutical Ltd, Bangladesh) at dose rate of 4 mg/Kg body weight (Fish et al., 2008), then Slightly lateral to site of superficial digital flexor tendon a straight 5 cm incision was made, including the skin, subcutaneous fascia and tendon paratenon, to expose the dorsal surface of the tendon, blunt dissection was performed to separate the superficial digital flexor tendon

Table 1: Histopathological index and scores

Index	Scores level	Description	Status
Angiogenesis	0	Small arteries oriented parallel to the collagen fibers	Normal
	1	Less than 25% irregular vascularization	Mild
	2	Less than 50% irregular thick walled vessels	Moderate
	3	More than 50% irregular thick walled vessels	Severe
Inflammatory cells	0	No inflammatory cells	Normal
	1	Less than 25% cellularity	Mild
	2	Less than 50% cellularity	Moderate
	3	More than 50% cellularity	Severe
Collagen fibers alignment	0	Dense, clearly defined regular parallel collagen orientation.	Normal
	1	Less than 25% of collagen fibers have irregular orientation.	Mild
	2	Less than 50% of collagen fibers have irregular orientation.	Moderate
	3	More than 50% of collagen fibers have irregular orientation.	Severe

Source: El-shafaey et al. (2013) and Schon et al. (2014).

from the corresponding tendon (deep digital flexor tendon), then curved artery forceps was inserted under the superficial tendon to expose it, two needles were placed at the proximal and distal side of the superficial digital flexor tendon to prevent tendon slipping, the SDFT was severed transversely with the scalpel, then approximated by Bunnell suture using polypropylene (3-0). These steps were followed in control group (first group), while in treatment groups; the same steps were performed in addition to wrapping the site of tenorrhaphy with platelet rich fibrin matrix in the second group, and with pericardium extracellular matrix in the third group. (5-0) USP polydioxanone was used to secure membranes in their position by interrupted stitches. (2-0) was used for subcutaneous fascia closure, finally the skin was closed using interrupted horizontal matters with silk (0), In all groups the site of operation was bandaged, and the operated limb immobilized using plaster of Paris cast (with window) for two weeks, postoperatively penicillin - streptomycin in a dose of 20000 I.U. and 10 mg/kg. B.W. respectively was administered intramuscularly for five days.

HISTOPATHOLOGICAL EVALUATION

Tendon biopsies were immersed in a buffer formalin solution 10% for histopathological study, formalin solution was changed after 72hr, then the sections were processed for hematoxylin - eosin and Van-Gieson's stain to observe the repair status of injured tendon site, analyzed semi-qualitatively according to El-shafaey et al. (2013) and Schon et al. (2014) using the parameters shown in Table 1.

STATISTICAL ANALYSIS

The Statistical Analysis System- SAS (2012) was used to influence of different aspects in study factors. Least significant difference -LSD analyze was used for significant compare between means.

RESULTS AND DISCUSSION

The histological sections of naive pericardium revealed the collagen fiber which appears red in color with clear fibroblasts in V.G stain (Figure 3A). While the histological sections of processed pericardium showed the collagen fiber red in color with few necrotic nuclei (Figure 3B). The histological sections of PRFM showed the fibrin network which appeared pinkish in color with aggregations of blood platelets red in color (Figure 3C). In First group (Control group), The main lesion at day 15 post-surgery showed the cellular collagen fiber extending into the incision area, with inflammatory cells infiltration (Figure 3D). Also myofibroblast proliferation was seen with few mononuclear cells infiltration and moderate collagen fiber with fibrin deposition, in addition to hemorrhage with congested blood vessels at the incision area). In V.G. stain, granulation tissue consisting from congested blood vessels with moderate irregular fibrous connective tissue which appears pale red in color was seen extended to the incision area (Figure 3E). At day 45 post-surgery the histopathological sections of the control group were characterized by high cellularity, irregular collagen fiber and irregular wave of fibroblast with moderate neovascular formation at the anastomotic site with mononuclear cell aggregation between the irregular collagen fibers (Figure 3F). In V.G. stain, the irregular collagen fiber appears red in color, infiltrated with mononuclear cells (Figure 4A). At day 75 post-surgery the main lesion showed the tendon fiber extended into the incision site between ends of the cut tendon which was filled with marked mononuclear cells infiltration and irregular fibrous connective tissue (Figure 4B). At day 180 post-surgery, the sections showed attachment between the newly formed tendon tissue with intact tissue by collagen fiber and dilated blood vessel characterized by enlarged endothelial cells with irregular few fibroblasts (Figure 4C). In Second

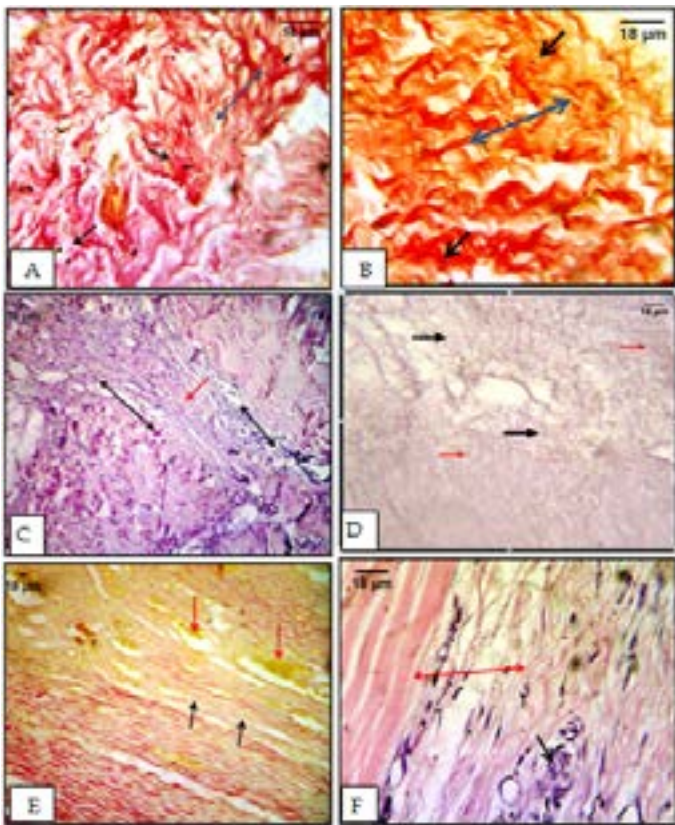


Figure 3: Appearance of collagen fiber (A) pericardium before processing, in Van-Gieson's stain, collagen fiber appear red in color (blue arrow) with clear fibroblasts (black arrows); (B) processed pericardium, In Van-Gieson's stain, dense less cellular irregular collagen fiber red in color (blue arrow) with absence of cellularity and few necrotic nuclei (black arrows); (C) PRFM, fibrin network appears pinkish in color (black arrows) with aggregations of blood platelets (red arrows); (D) Section in control group at day 15 postoperatively, the cellular collagen fiber (red arrow) with inflammatory cells infiltration (black arrows); (E) Section in control group at day 15 postoperatively, granulation tissue consisting from congested blood vessels (red arrow) with moderate irregular fibrous connective tissue pale red in color (black arrows); (F) Section in control group at day 45 postoperatively, mononuclear cells aggregation around few blood vessels (black arrow) with moderate irregular collagen fibers attached to a tendon fibers (red arrow).

group (PRFM group), at day 15 post-surgery the main lesion showed the anastomotic site filled with myofibroblasts and irregular collagen fiber with irregular orientation of fibroblast as compared to normal tendon tissues; Also suture materials were seen surrounded by fibrous connective tissue and tendon fiber extended from both ends into dense cellular collagen fiber in the tenorrhaphy site (Figure 4D). In V.G. stain sections showed the granulation tissue consist of blood vessels and irregular collagen fiber red in color (Figure 4E). At day 45 post-surgery, the sections showed granulation tissue infiltrated with inflammatory cells and moderate blood vessels with irregular collagen fiber; in addition to dark nuclei tenocyte which extended to the incision site (Figure 4F). In V.G. stain sections, showed the

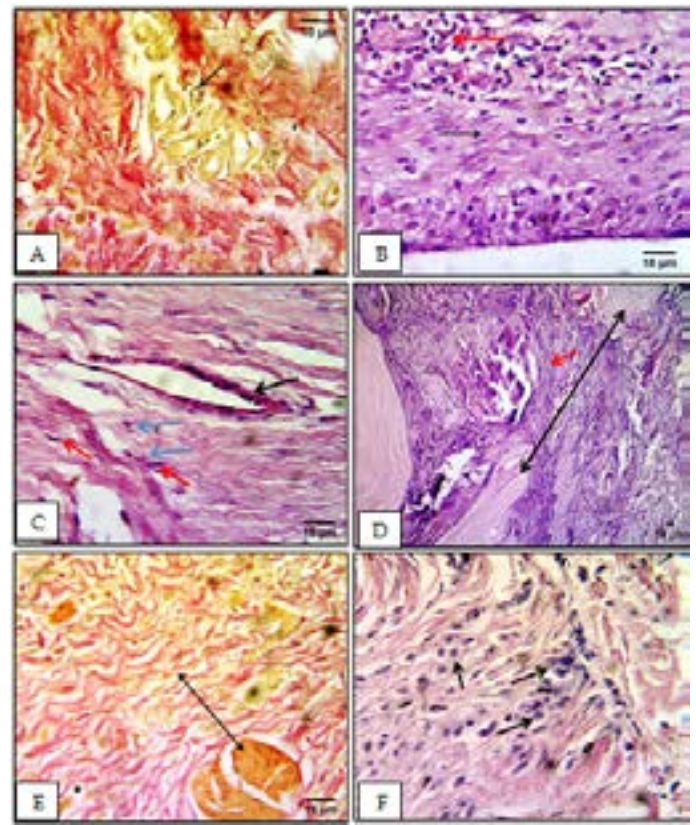


Figure 4: Performance of control group vs. PRFM group (A) Section in control group at day 45 postoperatively, the irregular collagen fibers, infiltrated with mononuclear cells (arrow) (V.G stain); (B) Section in control group at day 75 postoperatively, tendon fiber extending into the incision site (black arrow) infiltrated with marked mononuclear cells and irregular fibrous connective tissues (red arrow) (H&E stain); (C) Section in control group at day 180 postoperatively, attachment between the newly formed tendon tissue with intact tissue (blue arrows) and dilated blood vessels with enlarged endothelial cell (black arrow) and irregular few fibroblasts (red arrows) (H&E stain); (D) Section in PRFM group at day 15 postoperatively, suture materials surrounded by fibrous connective tissue (red arrow) and tendon fibers extending from both ends (black arrow) into dense cellular collagen fibers in the incision site (blue arrow) (H&E stain); (E) Section in PRFM group at day 15 postoperatively, granulation tissue consists of blood vessels and dense irregular collagen fibers red in color (arrow) (V.G stain); (F) Section in PRFM group at day 45 postoperatively, shows dark nuclei tenocyte extending to the incision site (arrows) (H&E stain).

tendon tissue appeared to be extended into the granulation tissue which was characterized by irregular collagen fiber red in color with congested blood vessels (Figure 5A). At day 75 postoperation, the sections showed new tendon fiber surrounded by a wave of irregular orientation of fibroblasts and irregular vascular collagen fibers (Figure 5B). In V.G. stain, the irregular collagen fiber red in color had extended to yellowish red granulation tissue (Figure 5C). At day 180 post-surgery, histopathological sections showed the two ends of cut tendon attachment by vascular tissue

with marked mononuclear cells particularly macrophages infiltration around new tendon fiber (Figure 5D). In V.G. stain sections, vascular granulation tissue contact the two parts of the severed tendon were seen (Figure 5E). In third group (PECM group), Histopathological sections at day 15 postoperatively, showed mononuclear cells infiltration between regular collagen fibers which extended into the incision area with few blood vessels; The tendon fiber with marked proliferation of their tenocytes was seen in the incision area which expressed moderate collagen fiber and mononuclear cells infiltration (Figure 5F).

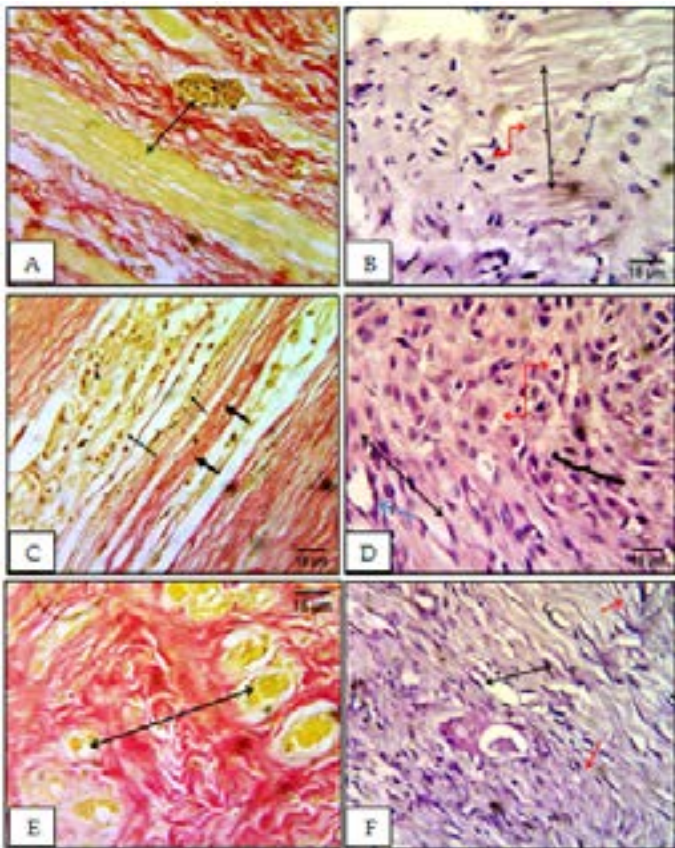


Figure 5: Performance of PRFM group (A) Section in PRFM group at day 45 postoperatively, dark nuclei tenocyte extending to the incision site (arrows) (H&E stain); (B) Section in the PRFM group at day 45 postoperatively, tendon fibers extending into granulation tissue which is characterized by irregular collagen fibers red in color with congested blood vessels (arrow) (V.G stain); (C) Section in PRFM group at day 75 postoperatively, tendon fibers (black arrow) surrounded by irregular waves of fibroblasts (blue arrow) and irregular vascular collagen fibers (red arrow) (H&E stain); (D) Section in PRFM group at day 75 postoperatively, the tendon fibers red in color (thick arrows) extending to immature granulation tissue, yellowish red in color (thin arrows) (V.G stain); (E) Section in PRFM group at day 180, the attachment of the anastomotic tendon ends (black arrow) by vascular tissue (blue arrow) with marked mononuclear cells infiltration around new tendon fibers in the incision area (red arrow) (H&E stain); (F) Section in PRFM group at day 180 postoperatively, vascular granulation tissue connecting the anastomotic tendon ends (arrow) (V.G stain).

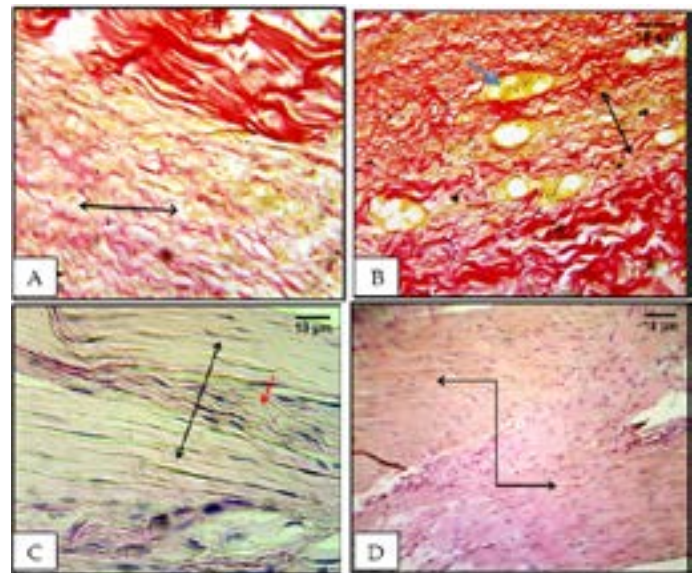


Figure 6: Performance of PECM group (A) Section in PECM group at day 15 postoperatively, red color regular collagen fibers with congested blood vessels (arrow) (V.G stain); (B) Section in PECM group at day 45 postoperatively, shows new tendon extending into the incision area (black arrow) surrounded by vascular tissues (blue arrow) (V.G stains); (C) Section in PECM group at day 75 postoperatively, tendon fibers (black arrow) surrounded by mature regular few cellular dense collagen fibers (red arrow) (H&E stain); (D) Section in PECM group at day 180 postoperatively, new tendon fibers similar to normal tendon fibers connecting the anastomotic ends of the tendon (arrow) (H&E stain).

In V.G. stain, shows red color regular collagen fiber with congested blood vessels (Figure 6A). At day 45 post surgery, section showed new tendon fiber extended into the incision site between ends of cut tendon surrounded by blood vessels (Figure 6B). At day 75 post surgery, tendon fibers seem to be similar to intact tendon fiber filling the incision site between cut ends of the tendon; Tendon fibers surrounded by mature, regular, less cellular and dense collagen fibers (Figure 6C). At day 180 post surgery, the sections showed highly cellular new tendon fiber similar to normal tendon connecting the two parts of the operated tendon (Figure 6D). This study revealed that the granulation tissue with congested blood vessels were significantly increased ($P \leq 0.05$) in PECM group at days 15 and 45 post surgery which graded (3), in comparison with the control and PRFM groups which was graded (2 and 2.5) respectively at day 15 and grade (1.5 and 2) at day 45 and still in same scores level to day 75 while the vascularization at this period was significantly decreased ($P \geq 0.05$) in PECM group which was graded (0.5) and remain in this level till day 180 while control and PRFM groups were graded (1). The inflammatory cells infiltration significantly increased ($P \leq 0.05$) as early as day 15 post-surgery in both treated groups which graded (3, 2.5) for PRFM and PECM respectively, while in control group graded (2)

Table 2: Mean values of histopathological scores

Time days	Index	Groups			LSD value
		Control	Fibrin	Pericardium	
15	Blood vessels	2 ^b	2.5 ^{ab}	3.0 ^a	0.84 *
	Inflammation	2 ^b	3 ^a	2.5 ^{ab}	0.81 *
	Fiber alignment	3 ^a	2 ^b	1.5 ^b	0.92 *
45	Blood vessels	1.5 ^b	2 ^b	3.0 ^a	0.92 *
	Inflammation	1.5 ^b	2.5 ^a	2.5 ^a	0.87 *
	Fiber alignment	1.5 ^a	0.7 ^b	0.0 ^b	0.76 *
75	Blood vessels	1.5 ^a	2.0 ^a	0.5 ^b	0.73 *
	Inflammation	1.0	1.7	1.0	0.76 NS
	Fiber alignment	1.5 ^a	0.5 ^b	0.0 ^b	0.75 *
180	Blood vessels	1.0	1.0	0.5	0.71 NS
	Inflammation	1.0	1.0	1.0	0.00 NS
	Fiber alignment	0.5	0.5	0.0	0.50 NS

* (P<0.05); NS: Non-significant; ^{a-b} = letters in same column indicate the means significantly different at (P<0.05); Number of animals 4/group.

and then decreased with time which graded (2.5) in both treated groups and grade (1.5) in control group at day 45. At days 75 and 180 there was no significant differences (P>0.05) among groups. The collagen fiber deposition and orientation were significantly increased in both treated groups at day 15 which graded (2 and 1.5) in PRFM and PECM groups respectively, while in control group graded (3) and the complete alignment of the collagen fibers noticed in PECM group at day 45 post-surgery which graded (0), while in control and PRFM groups graded (1.5, 0.7) and (1.5, 0.5) respectively at days 45 and 75 and they still not completely oriented till day 180 post-surgery which graded (0.5) in both groups as shown in (Table 2). The results of this study are close to other studies which indicated that the scaffold makes a fibrous bridge for tendon healing, these scaffolds are essential for fibroblasts proliferation with new collagen deposition that appear oriented relatively as the normal tendon (Demirkan et al., 2004; Rossouw and Villiers, 2005; El-Shfaey et al., 2012). In present study, the application of both platelet rich fibrin and pericardium extracellular matrices at the tenorrhaphy site assist in establishment of injured tendon continuity by attraction of inflammatory cells to the injured site and lead to acceleration of tendon healing. This result is supported by some investigators who indicated that the fibrin matrix concentrated with platelets which release the growth factors such as PDGF, TGF-β1, IGF-1, VEGF, HGF, some of these factors bind to a fibrin matrix and released slowly which lead to stimulation of cell proliferation, neovascularization and collagen synthesis (Anitua et al., 2006). Pericardium extracellular matrix attract the inflammatory cells represented by neutrophil, lymphocyte and macrophages which were infiltrated the injured site; the neutrophils are the main cells of early acute stage of inflammation which play an important role in phagocytosis (Palmer et al., 2002; Oryan et al., 2012), also macrophages infiltrated and play

important role in growth factors and cytokines delivering and facilitate the conversion of the inflammatory phase to proliferative stage (Wray and Orwin, 2009; Peng et al., 2010; Moshiri and Oryan, 2012). Current histopathological observations of treated groups are supported by the explanation of some investigators who revealed that the combination of neutrophils, macrophages, injured tendon cells and platelets, deliver growth factors, cytokines and chemo-attractants to the injured site which regulate fibroblasts migration, proliferation and differentiation (Moshiri and Oryan, 2012; Oryan et al., 2012). In control group the inflammatory response was less noticed as compared to treated groups which were characterized by increased inflammatory cells infiltration at the injured site this improved the development of granulation tissue in the tenorrhaphy site and this result are similar to Meimandi-Parizi (2013). The evidence of cellular infiltration into the scaffold may indicate fibroblasts invasion into the scaffold and integrated the scaffold with the tendon and surrounding tissues before ultimate deterioration which may restrict fibrosis and tendon contracture (Sarrafian et al., 2010). In addition, increased inflammation in PECM group in this study may be related to a cross linked pericardium scaffold which was used and this came in accordance with the opinion of some investigators who revealed that the cross linking masked the surface proteins and thereby decreased antigenicity and this would normally initiate a cellular hypersensitivity response (Jarman-Smith et al., 2004; Coons and Alan, 2006). The increase blood vessels at early stages occur according to suggestion that the injured tendon suffer from decreased blood nutrition and hypoxia that activated macrophages to release angiogenic factors represented by VEGF which initiate the angiogenesis in injured site (Allman et al., 2001), also the endothelial cells aggregate in the granulation tissue which lead to proliferation and regeneration of blood vessels (Fini et al., 2007; Oryan and

Shoushtari, 2008). Both the PECM and PRFM play an important role in alignment of the new collagen fibers this related to the scaffold fibers alignment, Saeidi et al. (2012) referred that organized scaffold produced highly organized tissue. Liu et al. (2012) explain that arrangement of collagen scaffold has an important role in cellular arrangement in vitro. Cardwell et al. (2012) also reported that large fibers are more efficient than arranged fibers in cell attitude in vitro. In present study both PRFM and PECM are considered as a 3D- architecture aligned in nature these matrices degraded gradually and its remnant act as micro scaffolds for newly tendon formation that result in healing tissue augmentation along the normal orientation of tendon fibers (Meimandi-Parizi et al., 2013).

CONCLUSION

Pericardium extracellular matrix and platelet rich plasma are easily prepared, do not require special equipment, cheap and easy to apply during operation, they are biocompatible and biodegradable in vivo and the PECM gave better results in healing of severed SDFT and increased collagen deposition and alignment, as well as the PRFM seems to enhance early healing process which is then decreased with long follow up. Therefore, using platelet rich fibrin or pericardium extracellular matrices is considered as a novel tissue engineering strategies in repair of SDFT.

ACKNOWLEDGMENTS

Authors acknowledge to the department of Pathology, College of Veterinary Medicine, Baghdad, Iraq.

CONFLICT OF INTEREST

The authors declare that they have no conflict of interests.

AUTHORS CONTRIBUTION

All the authors participated in the design of the experiment, read and approved the final paper.

REFERENCES

- Allman AJ, McPherson TB, Badylak SF, Merrill LC, Kallakury B (2001). Xenogeneic extracellular matrix grafts elicit a Th2 restricted immune response. *Transplantation*. 71: 1631-1640. <http://dx.doi.org/10.1097/00007890-200106150-00024>
- Anitua E, Sanchez M, Nurden AT, Zalduendo M, dela Fuente M, Orive G, Azofra J, Andia I (2006). Autologous fibrin matrices: A potential source of biological mediators that modulate tendon cell activities. *Wiley Period.* 77(2): 285-293. <http://dx.doi.org/10.1002/jbm.a.30585>
- Brennan EP, Janet RMS, Douglas CBS, Myers-Irvin M, Young EJ, Badylak SF (2006). Antibacterial Activity within degradation products of biological scaffolds composed of

extracellular matrix. *Tissue Eng.* 12(10): 2949 -2955. <http://dx.doi.org/10.1089/ten.2006.12.2949>

- Cardwell RD, Dahlgren LA, Goldstein AS (2012). Electrospun fiber diameter, not alignment, affects mesenchymal stem cell differentiation into the tendon/ligament lineage. *J. Tissue Eng. Reg. Med.* 8(12): 937-945. <http://dx.doi.org/10.1002/term.1589>
- Coons DA, Alan BF (2006). Tendon graft substituted rotator cuff patches. *Sports Med. Arthrosc.* 14: 185-190. <http://dx.doi.org/10.1097/00132585-200609000-00011>
- Demirkan I, Atalan G, Cihan M, Sozmen M (2004). Replacement of ruptured Achilles tendon by fascia lata grafting. *Vet. Cerrahi. Dergisi.* 10: 21-26.
- Dohan DM, Choukroun J, Diss A, Dohan SL, Dohan AJ, Mouhyi J (2006). Platelet rich fibrin (PRF): a second-generation platelet concentrate. Part I: Technological concepts and evolution. *Oral Surg. Med. Pathol. Radiol. Endod.* 101(3): 37- 44. <http://dx.doi.org/10.1016/j.tripleo.2005.07.008>
- El-Shafae EA, Karrouf GI, Zaghoul AE (2013). Clinical and biomechanical evaluation of three bioscaffold augmentation devices used for superficial digital flexor tenorrhaphy in donkeys (*Equus asinus*): An experimental study. *J. Adv. Res.* 4:103-113. <http://dx.doi.org/10.1016/j.jare.2012.02.001>
- Fini M, Torricelli P, Giavaresi G, Rotini R, Castagna A (2007). *In vitro* study comparing two collagenous membranes in view of their clinical application for rotator cuff tendon regeneration. *J. Orthop. Res.* 25: 98-107. <http://dx.doi.org/10.1002/jor.20295>
- Fish RE, Brown MJ, Danneman PJ, Karas AZ (2008). Anesthesia and analgesia in laboratory animals. 2nd ed. New York Academic Press. Pp. 385-411. <http://dx.doi.org/10.1016/B978-012373898-1.00014-1>
- Freytes DO, Martin J, Velankar SS, Lee AS, Badylak SF (2008). Preparation and rheological characterization of a gel form of the porcine urinary bladder matrix. *Biomaterials.* 29: 1630-1637. <http://dx.doi.org/10.1016/j.biomaterials.2007.12.014>
- Gigante A, Cesari E, Busilacchi A, Manzotti S, Kyriakidou K, Greco F (2009). Collagen I membranes for tendon repair: effect of collagen fiber orientation on cell behavior. *J. Orthop. Res.* 27(6): 826-832. <http://dx.doi.org/10.1002/jor.20812>
- Hao W, Pang L, Jiang M, Lv R, Xiong Z, Hu YY (2010). Skeletal repair in rabbits using a novel biomimetic composite based on adipose-derived stem cells encapsulated in collagen I gel with PLGA-beta-TCP scaffold. *J. Orthop. Res.* 28(2): 252-257.
- Jarman-Smith ML, Bodamyali T, Stevens C, Howell JA, Horrocks M, Chaudhuri JB (2004). Porcine collagen cross-linking, degradation and its capability for fibroblast adhesion and proliferation. *J. Mater. Sci. Mater. Med.* 15: 925-932. <http://dx.doi.org/10.1023/B:JMSM.0000036281.47596.cc>
- Juncosa-Melvin N, Boivin GP, Galloway MT, Gooch C, West JR, Sklenka AM (2005). Effects of cell-to-collagen ratio in mesenchymal stem cell-seeded implants on tendon repair biomechanics and histology. *Tissue Eng.* 11(3): 448-457. <http://dx.doi.org/10.1089/ten.2005.11.448>
- Kim TG, Chung HJ, Park TG (2008). Macroporous and nanofibrous hyaluronic acid/ collagen hybrid scaffold fabricated by concurrent electrospinning and deposition/ leaching of salt particles. *Acta. Biomater.* 4(6): 1611-1619. <http://dx.doi.org/10.1016/j.actbio.2008.06.008>
- Lee DK (2008). A preliminary study on the effects of acellular tissue graft augmentation in acute Achilles tendon ruptures.

- J. Foot Ankle Surg. 47(1): 8-12. <http://dx.doi.org/10.1053/j.jfas.2007.08.015>
- Liu Y, Zhang L, Li H, Yan S, Yu J (2012). Electrospun fibrous mats on lithographically micro patterned collectors to control cellular behaviors. *Langmuir*. 28: 17134-17142. <http://dx.doi.org/10.1021/la303490x>
 - Meimandi-Parizi A, Oryan A, Moshir A (2013). Tendon tissue engineering and its role on healing of the experimentally induced large tendon defect model in rabbits: A comprehensive *in vivo* study. *Tissue Eng. Tendon Heal*. 8(9): e73016.
 - Moshiri A, Oryan A (2012). Role of tissue engineering in tendon reconstructive surgery and regenerative medicine: current concepts, approaches and concerns. *Hard Tissue*. 1: 11. <http://dx.doi.org/10.13172/2050-2303-1-2-291>
 - Nicholson, G.P.; Breur, G.J.; Sickle, D.V.; Yao, J.Q.; Kim, J. and Blanchard, C.R. (2007). Evaluation of a cross-linked acellular porcine dermal patch for rotator cuff repair augmentation in an ovine model. *J. Shoulder Elbow Surg.*, 16(5): 184-190. <http://dx.doi.org/10.1016/j.jse.2007.03.010>
 - Nillesen STM, Lammers G, Wismans RG, Ulrich MM, Middelkoop E, Spauwen PH (2011). Design and *in vivo* evaluation of a molecularly defined acellular skin construct: Reduction of early contraction and increase in early blood vessel formation. *Acta. Biomater*. 7(3): 1063-1071. <http://dx.doi.org/10.1016/j.actbio.2010.10.011>
 - Oryan A, Shoushtari AH (2008). Histology and ultrastructure of the developing superficial digital flexor tendon in rabbits. *Anat. Histol. Embryol*. 37: 134-140. <http://dx.doi.org/10.1111/j.1439-0264.2007.00811.x>
 - Oryan A, Moshiri A, Sharifi P (2012). Advances in injured tendon engineering with emphasis on the role of collagen implants. *Hard Tissue*. 1(2): 12. <http://dx.doi.org/10.13172/2050-2303-1-2-292>
 - Oryan A, Silver IA, Goodship AE (2010). Metenperone enhances collagen turnover and remodeling in the early stages of healing of tendon injury in rabbit. *Arch. Orthop. Trauma Surg*. 130(12): 1451-1457. <http://dx.doi.org/10.1007/s00402-010-1057-8>
 - Palmer EM, Beilfuss BA, Nagai T, Semnani RT, Badylak SF (2002). Human helper T cell activation and differentiation is suppressed by porcine small intestinal submucosa. *Tissue Eng*. 8: 893-900. <http://dx.doi.org/10.1089/10763270260424259>
 - Peng YY, Glattauer V, Ramshaw JA, Werkmeister JA (2010). Evaluation of the immunogenicity and cell compatibility of avian collagen for biomedical applications. *J. Biomed. Mater. Res*. 93: 1235-1244.
 - Preeja C, Arun S (2013). Platelet-rich fibrin: Its role in periodontal regeneration. *Saudi J. Dental Res*. 5(2): 1-6.
 - Provencher MT, Mazzocca A, Romeo AA (2007). Biologics in rotator cuff surgery: Management of rotator cuff tears with an extracellular matrix patch. *Tech. Orthop*. 22(1): 43-54. <http://dx.doi.org/10.1097/01.bto.0000261758.10190.4e>
 - Rossouw P, Villiers M (2005). Bovine pericardial ligament and tendon augmentation: A new and revolutionary ligament. *J. Bone Joint Surg*. 3:277.
 - Saeidi N, Guo X, Hutcheon AE, Sander EA, Bale SS (2012). Disorganized collagen scaffold interferes with fibroblast mediated deposition of organized extracellular matrix *in vitro*. *Biotechnol. Bioeng*. 109: 2683-2698. <http://dx.doi.org/10.1002/bit.24533>
 - Sarrafian TL, Wang H, Hackett ES, Yao JQ, Shih MS, Ramsay HL (2010). Comparison of Achilles tendon repair techniques in a sheep model using a cross-linked acellular porcine dermal patch and platelet-rich plasma fibrin matrix for augmentation. *J. Foot Ankle Surg*. 49(2): 128-134. <http://dx.doi.org/10.1053/j.jfas.2009.12.005>
 - Schon LC, Gill N, Thorpe M, Davis J, Nadaud J, Kim J, Molligan J, Zhang Z (2014). Efficacy of a mesenchymal stem cell loaded surgical mesh for tendon repair in rats. *J. Trans. Med*. 12: 110. <http://dx.doi.org/10.1186/1479-5876-12-110>
 - Sharma P, Maffulli N (2008). Tendinopathy and tendon injury: The future. *Disabil. Rehabil*. 30(20): 1733-1745. <http://dx.doi.org/10.1080/09638280701788274>
 - Singh H, Kumar N, Sharma R, Dewangan R, Kumar A, Kumar V, Saxena P, Kumar S (2013). In vivo bio-compatibility determination of crosslinked as well as uncross linked native and acellular pericardium of buffalo. *Int. J. Bioassays*. 2(2): 391-397.
 - Song L, Olsen RE, Spalazzi JP, Davisson TW (2010). Biomechanical evaluation of acellular collagen matrix augmented Achilles tendon repair in sheep. *J. Foot Ankle Surg*. 49(5): 438-441. <http://dx.doi.org/10.1053/j.jfas.2010.06.009>
 - Wray LS, Orwin EJ (2009). Recreating the microenvironment of the native cornea for tissue engineering applications. *Tissue Eng*. 15: 1463-1472. <http://dx.doi.org/10.1089/ten.tea.2008.0239>